

Original Research Paper

# Clinical Analysis of Pulmonary Nocardiosis in a Tertiary Hospital

Yoshihiro Kobashi, Makoto Kittaka, Ryo Shirai, Shigeki Kato and Mikio Oka

Division of Respiratory Medicine, Kawasaki Medical School, Japan

## Article history

Received: 11-12-2017

Revised: 20-03-2018

Accepted: 31-03-2018

## Corresponding Author:

Yoshihiro Kobashi

Division of Respiratory  
Medicine, Kawasaki Medical  
School, Japan

Tel: +81-86-462-1111

Fax: +81-86-464-1041

E-mail: yoshihiro@med.kawasaki-  
m.ac.jp

**Abstract:** This study aimed to clarify the clinical characteristics of pulmonary nocardiosis in our tertiary hospital. The subjects consisted of five cases with pulmonary nocardiosis who received a definite diagnosis in our hospital from January 2006 to December 2016. The five patients with pulmonary nocardiosis included four females and one male with a mean age of 65.6 years old. All patients had underlying diseases. The detection methods were respiratory symptoms in four patients and an abnormal chest shadow in one. There were no characteristic laboratory findings. Regarding the radiological findings, an infiltration shadow was the most common finding in this study. In addition, a mass shadow that required differentiation from lung cancer was recognized in one patient. The diagnosis was reached using bronchoscopic specimens in all patients. The causative microorganisms consisted of *Nocardia farcinica* in three, *Nocardia puris* in one and *Nocardia elegans* in one. The drug susceptibility Trimethoprim/Sulfamethoxazole (TMP/SMZ) was sensitive in four of five patients. Although TMP/SMZ was administered to all patients as treatment, two patients required a change of antimicrobial agents because of adverse drug events. However, the clinical effect was good for all patients because of early treatment initiation. The conclusions of this study are as follows: (1) pulmonary nocardiosis occurs in immunocompetent patients with underlying respiratory diseases and patients undergoing immunosuppressive treatments; (2) there are no characteristic findings of pulmonary nocardiosis in the laboratory or radiological findings; (3) local respiratory clinical specimens using bronchoscopy were useful to obtain a definite diagnosis; (4) no patients had contracted TMP/SMZ-resistant *Nocardia* species and the clinical effect and prognosis were good.

**Keywords:** Pulmonary Nocardiosis, TMP/SMZ, Bronchoscopy

## Introduction

*Nocardia* is a genus of aerobic Gram positive bacilli that mainly affects immunocompromised patients such as those receiving immunosuppressive drugs for a long time, Acquired Immunodeficiency Syndrome (AIDS) patients and recipients of organ transplantations (Ambrosioni *et al.*, 2010). It causes infectious diseases including skin and pulmonary infections and disseminated diseases. Pulmonary nocardiosis is a rare infectious disease, but clinical findings in several recent reports have been noted (Kurihara *et al.*, 2014; Chen *et al.*,

2013; Garcia-Bellmunt *et al.*, 2012; Martinez Tomas *et al.*, 2007). If pulmonary nocardiosis is not diagnosed early enough to initiate the appropriate treatment, it results in high morbidity and poor prognosis (Brown-Elliott *et al.*, 2006; Lerner, 1996). However, an early diagnosis of pulmonary nocardiosis may be difficult because clinical signs or symptoms are nonspecific. Therefore, clinical suspicion of pulmonary nocardiosis is necessary. Because the taxonomy of *Nocardia* species has been changing, it is difficult to decide on a routine identification and molecular characterization (PCR-RFLP) of *Nocardia* isolates (Valenzuela-Tovar *et al.*,

2005). The taxonomy of *Nocardia* species has recently evolved and molecular methods such as 16s rRNA gene sequence analysis have led to a more appropriate classification (Wilson, 2012; Liu *et al.*, 2011).

The aim of this study was to investigate the clinical characteristics, microbiological findings (using molecular analysis as far as possible), treatment and prognosis for patients with pulmonary nocardiosis at a tertiary hospital in Japan.

## Patients and Methods

We selected patients diagnosed as pulmonary nocardiosis in Kawasaki Medical School Hospital, Kurashiki, Japan with a total capacity of 1182 beds, based on a retrospective review from January 2006 to December 2016. In this study, patients with no abnormal shadows in the lung radiologically despite the isolation of *Nocardia* species were excluded as airway *Nocardia* colonization. Pulmonary nocardiosis was defined as the presence of abnormal shadows radiologically, with *Nocardia* species isolated from respiratory clinical sample cultures at least once. This study protocol was approved by the Ethical Committee of Kawasaki Medical School.

Regarding the radiological findings, several pulmonary physicians and radiologists in our hospital retrospectively reviewed the Computed Tomography (CT). The reviewers classified cases using the following findings; airspace consolidation, nodules, cavity, ground glass opacity, pleural effusion and mass lesion.

Concerning microbiological identification, clinical specimens were smeared using Gram-staining to detect the presence of Gram-positive filamentous organisms, acid-fast stained using a modified method and incubated on agar plates. The identification of *Nocardia* species was performed using conventional biochemical tests for *Nocardia* (Saubolle and Sussland, 2003). Antimicrobial susceptibility testing was done using the disk diffusion method with several antibiotics including Trimethoprim/Sulfamethoxazole (TMP/SMZ) on Muller-

Hinton agar according to the National Committee for Clinical Laboratory Standards criteria (NCCLS, 2003). The identification of *Nocardia* species was confirmed by 16s ribosome RNA gene sequence analysis.

The following clinical data were collected from the medical records: Patient demographics, underlying diseases, clinical symptoms, laboratory findings, radiological findings, diagnostic methods, bacteriological findings including antimicrobial susceptibility, treatments and prognosis.

## Results

There were five patients with pulmonary nocardiosis in our tertiary hospital during the period of this study. The average age was 65.6 years old and there was one male and four females. One patient had a smoking history and all patients had underlying diseases. Three patients had underlying respiratory diseases such as bronchiectasis or Chronic Obstructive Lung Disease (COPD) and two patients had received immunosuppressive treatment. The chief complaints were respiratory symptoms such as cough or sputum in four patients and a chest abnormal shadow in one (Table 1).

The main laboratory findings of patients with pulmonary nocardiosis were a mild or moderate inflammatory response in all patients and hypoalbuminemia in four of five patients. Although QuantiFERON TB-Gold In-Tube (QFT-IT) showed a positive response in Case 1 and *Aspergillus* antigen showed a positive response in Case 4, *Mycobacterium* and *Fungus* species were not detected from the respiratory specimens from the lesions using bronchoscopy. There were no characteristic findings in the diagnosis of pulmonary nocardiosis (Table 1).

The radiographic findings using chest CT are shown in Table 2. The predominant findings were airspace consolidation (Fig. 1), but small nodules or a cavity were recognized in one patient. Only a mass shadow (30×35 mm) was present in the hilum of the right lower lobe and this required differentiation from primary lung cancer because of vascular indentation (Fig. 2).

**Table 1:** Clinical findings of pulmonary nocardiosis experienced in our hospital (1)

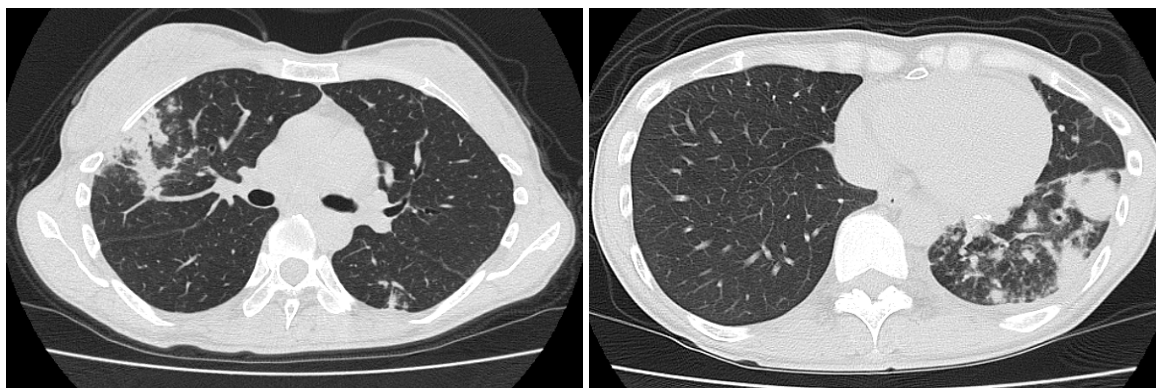Case	Age, Sex	Smoking history (Cigarette/day x years)	Underlying disease	Chief complaints	Laboratory findings						
					WBC (/μl)	CRP (mg/dl)	Tb (g/dl)	Alb (g/dl)	HIV	β-D-glucan (pg/ml)	others
1	50, F	(-)	Bronchiectasis Pneumonia Pleuritis	Fever Cough Sputum	5020	1.45	6.7	3.6	(-)	<6.0	QFT(+)
2	67, F	(-)	Bronchiectasis	Cough	4850	0.75	7.5	4.5	(-)	<6.0	(-)
3	80, F	(-)	Subarachnoid Hemorrhage Chronic sinusitis	Cough Sputum General fatigue	7660	1.31	7	3.5	(-)	<6.0	(-)
4	74, M	(+) (10×40)	COPD AIHA (Steroid)	Cough Sputum	10790	16.16	5.6	3.2	(-)	<6.0	<i>Aspergillus</i> antigen (+)
5	57, F	(-)	SLE (Steroid)	(-)	5820	0.53	5.7	3.3	(-)	<6.0	(-)

COPD: Chronic Obstructive Pulmonary Disease, AIHA: Autoimmune Hemolytic Anemia SLE: Systemic Lupus Erythematosus, WBC: White Blood Cell, CRP: C-reactive Protein, TP: Total Protein, Alb: Albumin, HIV: Human Immunodeficiency Virus

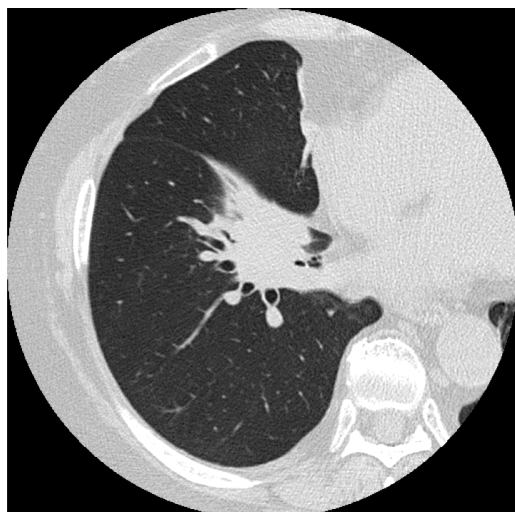
**Table 2:** Clinical findings of pulmonary nocardiosis experienced in our hospital (2)

Case	Radiological findings						Diagnostic method	Time to diagnosis	Causative microorganism	Drug sensitivity test (Resistant to TMP/SMZ)	Treatment	Prognosis
	Consolidation	Nodules	Cavity	GGO	Pleural effusion	Mass						
1	(+)	(-)	(-)	(-)	(-)	(-)	Bronchoscopy	2 weeks	<i>Nocardia farcinica</i>	(-)	TMP/SMZ (Stopped) ↓ LVFX (Poor) ↓ AMK IPM/cs ↓ TMP/SMZ (Good)	Survival (5 years)
2	(+)	(+)	(-)	(-)	(-)	(-)	Bronchoscopy	2 weeks	<i>Nocardia puris</i>	(-)	TMP/SMZ (Good)	Survival (6 months)
3	(+)	(-)	(-)	(+)	(-)	(-)	Bronchoscopy	3 weeks	<i>Nocardia farcinica</i>	(-)	TMP/SMZ (Stopped) ↓ MINO (Good))	Survival (5 years)
4	(+)	(-)	(+)	(-)	(-)	(-)	Bronchoscopy	2 weeks	<i>Nocardia farcinica</i>	N.D.	TMP/SMZ (Good)	(Death Other disease 9 years)
5	(-)	(-)	(-)	(-)	(-)	(+)	Bronchoscopy	6 weeks	<i>Nocardia elegans</i>	(-)	TMP/SMZ (Good)	Survival (6 months)

GGO: Ground Glass Opacity, N.D.: Not Done, TMP/SMZ: Trimethoprim-Sulfamethoxazole, LVFX: Levofloxacin, AMK: Amikacin, IPM/cs: Imipenem/ilastatin, MINO: Minocycline



**Fig. 1:** Chest CT on admission showing an infiltration shadow with bronchiectasis in the right upper lobe and left lower lobe. (Case 1)



**Fig. 2:** Chest CT on admission showing a mass shadow (30×35 mm) in the right hilum (headarrow). (Case 5)

The diagnostic methods consisted of culture of local respiratory clinical samples using bronchoscopy in all patients. The time required to obtain a definite diagnosis was from two to six weeks. Regarding the microbiological identification of *Nocardia* species using 16s rRNA gene sequence analysis, *N. farcinica* was most frequently found in three patients, *N. puris* in one and *N. elegans* in one, respectively. Other causative microorganisms such as Mycobacterium, fungus species or common bacteria were not detected respiratory specimens from the lesions using bronchoscopy in any patients. No patients had contracted TMP/SMZ-resistant *Nocardia* species in this study. The treatment for pulmonary nocardiosis consisted of TMP/SMZ antibiotics in the first protocol. However, two patients required a change of antimicrobial agents (MINO or IPM/CS) because of adverse drug events. Finally, the clinical effect and prognosis were good for all patients.

## Discussion

We tried to clarify the clinical characteristics of pulmonary nocardiosis experienced in our tertiary hospital in this study. In previous reports, pulmonary nocardiosis tended to affect patients in an immunocompromised condition due to corticosteroid drugs or biological drugs (Ambrosioni *et al.*, 2010) and with underlying respiratory diseases such as COPD (Kurihara *et al.*, 2014; Chen *et al.*, 2013; Menendez *et al.*, 1997). In our study, four of five patients with pulmonary nocardiosis received immunosuppressive drugs and had underlying respiratory diseases, as in previous studies.

Regarding the radiological findings on chest CT, the most common CT findings were airspace consolidation, nodules, pleural effusion and cavity formation (Blackmon *et al.*, 2011; Backley *et al.*, 1995). However, the radiological findings between immunocompetent patients and immunocompromised patients were different: Bronchiectasis and centrilobular nodular opacities in the former and nodules, masses, cavities in the latter (Biscione *et al.*, 2005). Otherwise, there were sometimes mixed infections with *Mycobacterium* or *Aspergillus* species in patients with pulmonary nocardiosis (Kurihara *et al.*, 2014; Chen *et al.*, 2013). Cavity formation was frequently recognized in these patients (Feigin, 1986). However, although we investigated the clinical specimens from the lesions obtained using bronchoscopy in this study, there were no patients with mixed infection with other microorganisms. Airspace consolidation was the most frequent finding in four cases and nodules, cavities or masses in one, respectively. Because there was no specific radiological pattern for pulmonary nocardiosis, it was difficult to distinguish it from other pulmonary infectious diseases such as pulmonary mycobacterial infection or mycosis in this study.

*Nocardia* is a Gram-positive aerobic bacilli and the taxonomy changes continuously. The final identification requires molecular techniques such as 16S rRNA sequencing analysis as in a recent study (Wilson, 2012; Liu *et al.*, 2011). We also identified *Nocardia spp.* using 16S rRNA with the assistance of a special institution in this study (Division of Mycology, National Institute of Infectious Diseases and Medical Mycology Research Center, Chiba University). Subsequently, *N. farcinica* was most frequently identified in three of five patients and *N. puris*, *N. elegans* in one, respectively. Concerning the identification of *Nocardia* species using the 16S rRNA technique, while Chen *et al.* reported that *N. cyriacigeorgica* was most frequently identified in Taiwan and recognized in clinically severe cases (Chen *et al.*, 2013). Hui *et al.* (2013) reported that *N. asteroides* was

most frequently identified in Australia. Considering these previous reports, the difference in identified *Nocardia* species may depend on the difference in the distribution pattern in the community. Regarding the antimicrobial susceptibility of *Nocardia* species, although we sent the *Nocardia* isolates to a special mycology institution and measured the susceptibility for many antibiotics in four of five patients, there was no resistance to TMP/SMZ in any patients. On the other hand, Kuwahara *et al.* reported that 27% of *Nocardia* species were resistant to TMP/SMZ. In particular, both *N. farcinica* and *N. otitidiscaviarum* showed resistance to TMP/SMZ in many patients with pulmonary nocardiosis (Kurihara *et al.*, 2014). Generally, *N. farcinica* is associated with antibiotic resistance and poor outcomes (Husain *et al.*, 2002; Wallace *et al.*, 1990). However, antimicrobial susceptibility results for this microorganism have recently varied (Brown-Elliott *et al.*, 2012; Uhde *et al.*, 2010) and it was reported that there are several problems in the inter-laboratory reproducibility of the TMP/SMZ susceptibility test (Conville *et al.*, 2012). Therefore, we consider that it is necessary to reevaluate the relationship between susceptibility tests for antibiotics and clinical effect by linking many laboratory centers around the world.

In the treatment of pulmonary nocardiosis, because the translation rate for the cerebroneurological system of TMP/SMZ has been good, TMP/SMZ have been recommended as the first choice antibiotics for the treatment for *Nocardia* infection (Sorrell *et al.*, 2005). However, it was reported that TMP/SMZ often caused adverse events and treatment had to be stopped. In this study, TMP/SMZ was administered to all patients, but adverse events appeared in two patients and they had to stop this treatment. When TMP/SMZ cannot be administered due to adverse events, it was reported that amoxicillin/clavulanic acid, MINO, IPM/CS, AMK or CTRX were useful as the second choice antibiotics for the treatment of pulmonary nocardiosis (Menendez *et al.*, 1997; McNeil *et al.*, 1995). Therefore, we selected AMK, IPM/CS and MINO, which showed good sensitivity for the individual patient. Regarding the duration of treatment using TMP/SMZ for pulmonary nocardiosis, Sorrell *et al.* (2005) reported that at least six months was required for immunocompetent patients with pulmonary or general nocardiosis or immunosuppressed HIV-negative patients. We also think it necessary to administer TMP/SMZ for six months for similar patients and administered to our patients for over six months except for two patients that stopped due to adverse events. However, because there was no evidence about the recommended dose and duration for other antibiotics, a prospective large scale study should be performed for other antibiotics besides TMP/SMZ.

Concerning the prognosis of *Nocardia* infection, the mortality rate due to nocardiosis was poor (80%) in previous reports (Presant *et al.*, 1973). However, the mortality rate has decreased to 20% with the appearance of TMP/SMZ (Lederman and Crum, 2004) and the pulmonary nocardiosis survival rates were reported to be 97% (after 30 days), 83% (after 90 days) and 74% (after 180 days) in a recent Japanese report (Kurihara *et al.*, 2014). While the prognosis of pulmonary nocardiosis was good, it was reported that the prognosis was worse when the patient showed a disseminated type or cerebral nocardiosis was complicated, (Yorke, 2003; Menendez *et al.*, 1997; Lerner, 1995). Although there were several patients with pulmonary nocardiosis in our study, no patients died due to the worsening of pulmonary nocardiosis and only one patient died due to another disease during the follow-up period after the remission of pulmonary nocardiosis. As one reason for the good prognosis, we think that the positive diagnostic method using bronchoscopy was related to the early diagnosis within a few weeks and initiation of treatment in all patients excluding one (Case 6) in this study.

Finally, this study has a few limitations due to its retrospective nature. Firstly, because this study was performed in a single tertiary hospital and excluded patients suspected of airway *Nocardia* colonization, it was small scale with only five patients with pulmonary nocardiosis. Secondly, although we reported that there were no patients with other infectious diseases except for pulmonary nocardiosis from the culture results of the local specimens from lesions using bronchoscopy, we cannot exclude the possibility of co-infection with other microorganisms completely as the clinical data were collected from the medical previous records based on a retrospective review.

## Conclusion

The conclusions of this study are as follows: (1) pulmonary nocardiosis occurs in immunocompetent patients with underlying respiratory diseases and patients undergoing immunosuppressive treatments; (2) there are no characteristic findings of pulmonary nocardiosis in the laboratory or radiological findings; (3) the local respiratory clinical specimens using bronchoscopy were useful to obtain a definite diagnosis; (4) no patients had contracted TMP/SMZ-resistant *Nocardia* species and the clinical effect and prognosis were good.

## Acknowledgment

The investigators would like to thank Dr. Daigo Tanimoto, Division of Radiological diagnosis, Kawasaki Medical School, Dr. Takashi Yaguchi, Medical Mycology Research Center, Chiba University and Dr. Yoshitsugu Miyazaki, Division of Mycology, National Institute of Infectious Diseases for microbiological analysis.

## Author's Contributions

**Yoshihiro Kobashi:** Research plan and organized the study writing of the manuscript.

**Makoto Kittaka and Ryo Shirai:** Help of writing of the manuscript.

**Shigeki Kato:** Check of the manuscript.

**Mikio Oka:** Final check of the manuscript.

## Competing Interest

The authors declare that they have no competing interest.

## References

- Ambrosioni, J., D. Lew and J. Garbino, 2010. Nocardiosis: Updated clinical review and experience at a tertiary center. *Infection*, 38: 89-97.  
DOI: 10.1007/s15010-009-9193-9
- Backley, J.A., A.R. Padkani and J.E. Kuhlman, 1995. CT features of pulmonary nocardiosis. *J. Comp. Assis. Tomogr.*, 19: 726-732.  
DOI: 10.1097/00004728-199509000-00007
- Biscione, F., D. Cecchini, J. Ambrosioni, M. Bianchi and M. Corti *et al.*, 2005. Nocardiosis in patients with human immunodeficiency virus infection. *Enferm. Infect. Microbiol. Clin.*, 23: 419-423.  
DOI: 10.1157/13078801
- Blackmon, K.N., J.G. Ravenal, J.M. Gomez, J. Ciolino and D.W. Wray, 2011. Pulmonary nocardiosis: Computed tomography features at diagnosis. *J. Thorac. Imag.*, 26: 224-229.  
DOI: 10.1097/RTI.0b013e3181f45dd5
- Brown-Elliott, B.A., J.M. Brown, P.S. Conville and R.J. Wallace, Jr, 2006. Clinical and laboratory features of the *Nocardia* spp. based on current molecular taxonomy. *Clin. Microbiol. Rev.*, 19: 259-282.  
DOI: 10.1128/CMR.19.2.259-282.2006
- Brown-Elliott, B.A., J. Biehle, P.S. Conville, S. Cohen and M. Saubolle *et al.*, 2012. Sulfonamide resistance in isolates of *Nocardia* spp. from a U.S. multicenter survey. *J. Clin. Microbiol.*, 50: 670-672.  
DOI: 10.1128/JCM.06243-11
- Chen, Y.C., C.H. Lee, C.C. Chien, T.L. Chao and W.C. Lin *et al.*, 2013. Pulmonary nocardiosis in southern Taiwan. *J. Microbiol. Immunol. Infect.*, 46: 441-447.  
DOI: 10.1016/j.jmii.2012.07.017
- Conville, P.S., B.A. Brown-Elliott, R.J. Wallace, Jr, F.G. Wiebsky and D. Koziol *et al.*, 2012. Multisite reproducibility of the broth microdilution method for susceptibility testing of *Nocardia* species. *J. Clin. Microbiol.*, 50: 1270-1280.  
DOI: 10.1128/JCM.00994-11

- Feigin, D.S., 1986. Nocardiosis of the lung: Chest radiographic findings in 21 cases. *Radiology*, 159: 9-14. DOI: 10.1148/radiology.159.1.3952335
- Garcia-Bellmunt, L., O. Sibila, I. Solanes, F. Sanchez-Reus and V. Plaza, 2012. Pulmonary nocardiosis in patients with COPD: Characteristics and prognostic factors. *Arch. Broncopneumol.*, 48: 280-285. DOI: 10.1016/j.arbr.2012.06.006
- Hui, C.H., V.W. Au, K. Rowland, J.P. Slavotinek and D.L. Gordon, 2003. Pulmonary nocardiosis re-visited: Experience of 35 patients at diagnosis. *Respir. Med.*, 97: 709-717. DOI: 10.1053/rmed.2003.1505
- Husain, S., K. McCurry, J. Dauber, N. Siagh, and S. Kusne, 2002. Nocardia infection in lung transplant recipients. *J. Heat Lung Transplant.*, 21: 354-359. DOI: 10.1016/S1053-2498(01)00394-1
- Kurihara, Y., K. Tachibana, K. Tsuyuguchi, M. Akira and K. Suzuki *et al.*, 2014. Pulmonary nocardiosis: A clinical analysis of 59 cases. *Respiratory Invest.*, 52: 160-166. DOI: 10.1016/j.resinv.2013.09.004
- Lederman, E.R. and N.F. Crum, 2004. A case series and focused review of nocardiosis: Clinical and microbiologic aspects. *Medicine*, 83: 300-313. DOI: 10.1097/01.md.0000141100.30871.39
- Lerner, P.I., 1996. Nocardiosis. *Clin. Infect. Dis.*, 22: 891-903. DOI: 10.1093/clinids/22.6.891
- Lerner, P.I., 1995. Nocardia Species. In: Principles and Practice of Infectious Diseases, Mandell, G.L. (Eds.), Churchill Livingstone, New York, pp: 2273-2280.
- Liu, W.L., C.C. Lai, W.C. Ko, Y.H. Chen and H.J. Tang *et al.*, 2011. Clinical and microbiological characteristics of infections caused by various *Nocardia* species in Taiwan: A multicenter study from 1998 to 2010. *Eur. J. Clin. Microbiol. Infect. Dis.*, 30: 1141-1147. DOI: 10.1007/s10096-011-1227-9
- Martinez Tomas, R., R.M. Villanueva, S.R. Calzada, M.S. Durantez and J.M.V. Tarazona *et al.*, 2007. Pulmonary nocardiosis: Risk factors and outcomes. *Respirology*, 12: 394-400. DOI: 10.1111/j.1440-1843.2007.01078.x
- Menendez, R., P.J. Cordero, M. Santos, M. Goberbado and V. Marco, 1997. Pulmonary infection with *Nocardia* species: A report of 10 cases and review. *Eur. Respir. J.*, 10: 1542-1546. DOI: 10.1183/09031936.97.10071542
- McNeil, M.M., J.M. Brown, L.C. Hutwagner and T.A. Schiff, 1995. Evaluation of therapy for *Nocardia asteroides* complex infections. *Infect. Dis. Clin. Pract.*, 4: 287-292. DOI: 10.1097/00019048-199507000-00011
- NCCLS, 2003. Susceptibility testing of mycobacteria, nocardia and other aerobic actinomycetes. Approved Standard NCCLS Document M24-A.
- Presant, C.A., P.H. Wiemik and A.A. Serpick, 1973. Factors affecting survival in nocardiosis. *Am. Rev. Respir. Dis.*, 108: 1444-1448. DOI: 10.1164/arrd.1973.108.6.1444
- Saubolle, M.A. and D. Sussland, 2003. Nocardiosis: Review of clinical and laboratory experience. *J. Clin. Microbiol.*, 41: 4497-4501. DOI: 10.1128/JCM.41.10.4497-4501.2003
- Sorrell, T.C., D.H. Mitchell and J.R. Iredell, 2005. *Nocardia* Species. In: Principles and Practice of Infectious Diseases, Mandell, G.L., J.E. Bennet and R. Dolon (Eds.), Churchill Livingstone, USA, pp: 2916-2924.
- Uhde, K.B., S. Pathan, I. McCullium, Jr., D.P. Jannat-Khah and S.V. Shadomy *et al.*, 2010. Antimicrobial-resistant nocardia isolates, United States, 1995-2004. *Clin. Infect. Dis.*, 51: 1445-1448. DOI: 10.1086/657399
- Valenzuela-Tovar, J.F., C. Contreras-Perez, H. Shibayama-Hernandez, L. Chavez-Gonzalez and C.A. Vazquez-Chacon *et al.*, 2005. Biochemical identification and molecular characterization (PCR-RFLP) of *Nocardia* isolates from sputum. *Arch. Med. Res.*, 36: 355-361. DOI: 10.1016/j.arcmed.2005.03.031
- Wallace, Jr, R.J., M. Tsukamura, B.A. Brown, J. Brown and V.A. Steingrube *et al.*, 1990. Cefotaxime-resistant *Nocardia asteroides* strains are isolates of the controversial species *Nocardia farcinica*. *J. Clin. Microbiol.*, 28: 2726-2732. PMID: 2280003
- Wilson, J.W., 2012. Nocardiosis: Updates and clinical overview. *Mayo Clin. Proc*, 87: 403-407. DOI: 10.1016/j.mayocp.2011.11.016
- Yorke, R.F., 2003. Nocardiosis with brain abscess due to an unusual species, *Nocardia transvalensis*. *Arch. Pathol. Lab. Med*, 127: 224-226. DOI: 10.1043/0003-9985(2003)127<224:NWBADT>2.0.CO;2